



Raikhan Bolatbekova
Kazakhstan Cancer Society

Patient 1, 43y.o.

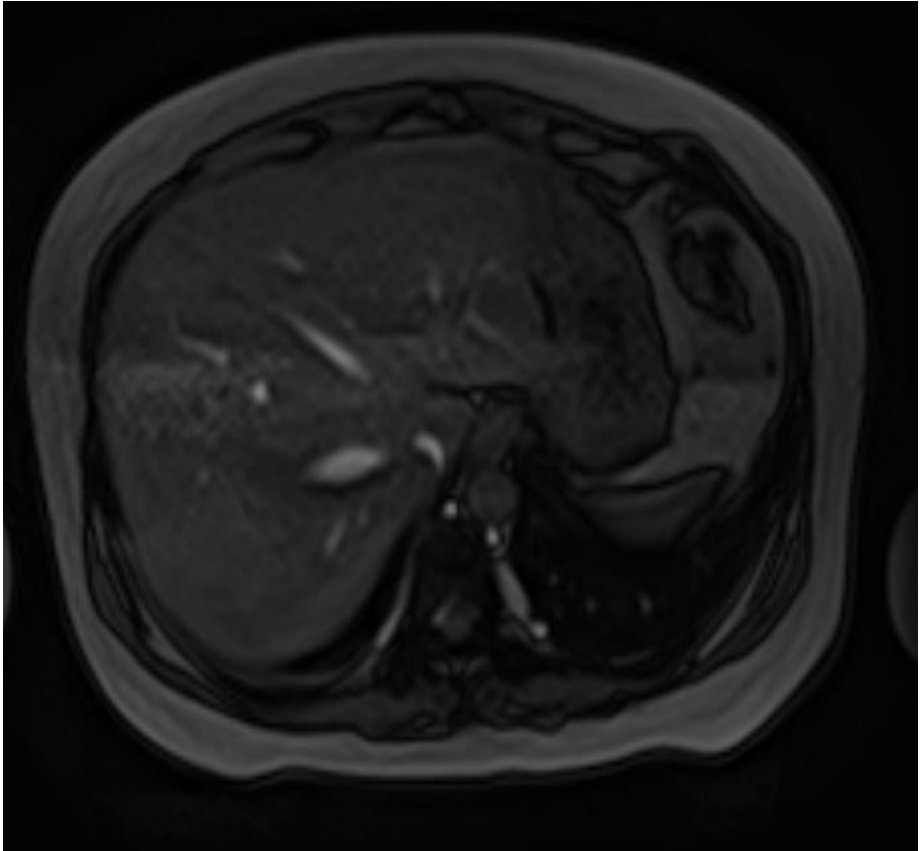
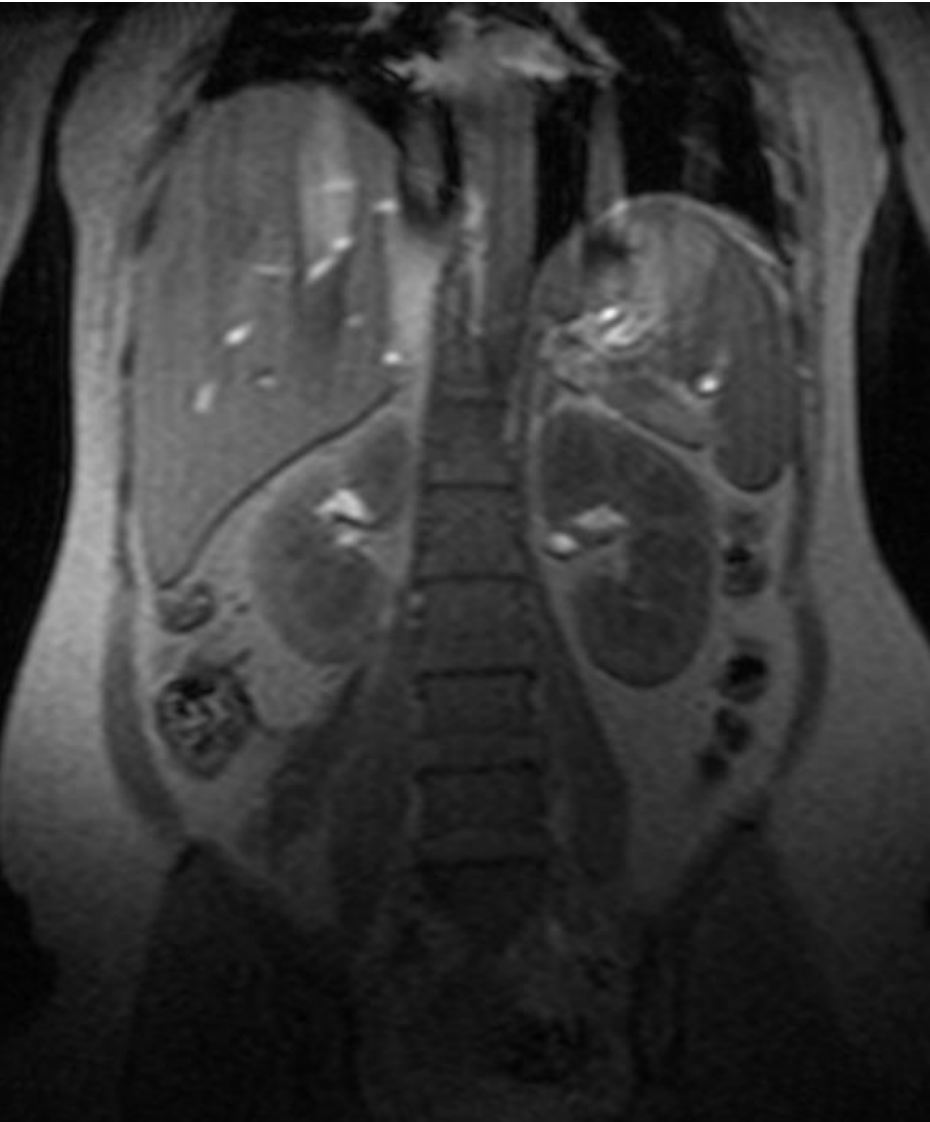
August 2021 43-year-old G(4)P(3) pregnant woman was presented with abnormal bleeding.

No abdominal pain, fever, or other discomfort was noted
ECOG 0

Gynecological examination showed the uterine height was 25 cm, and the abdominal circumference was 98 cm. The cervix was hypertrophic, with a 4-cm myoma-like neoplasm visible at its lower lip and the parametrium was soft. The lesion demonstrated contact bleeding

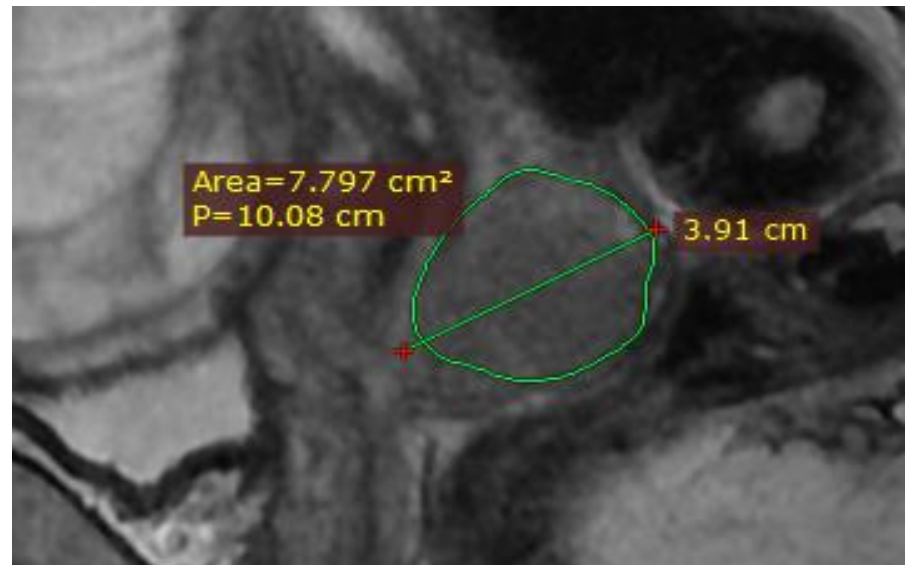
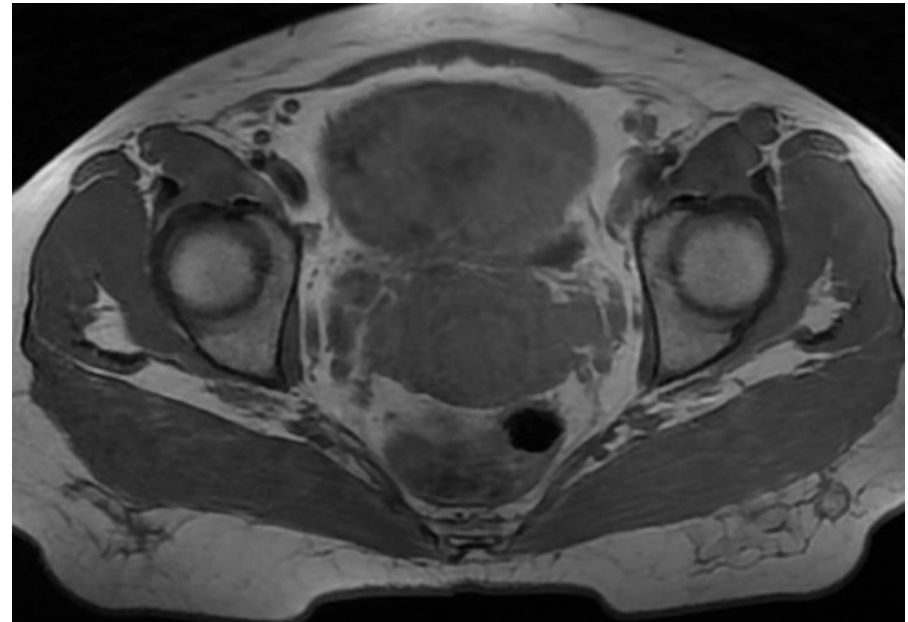
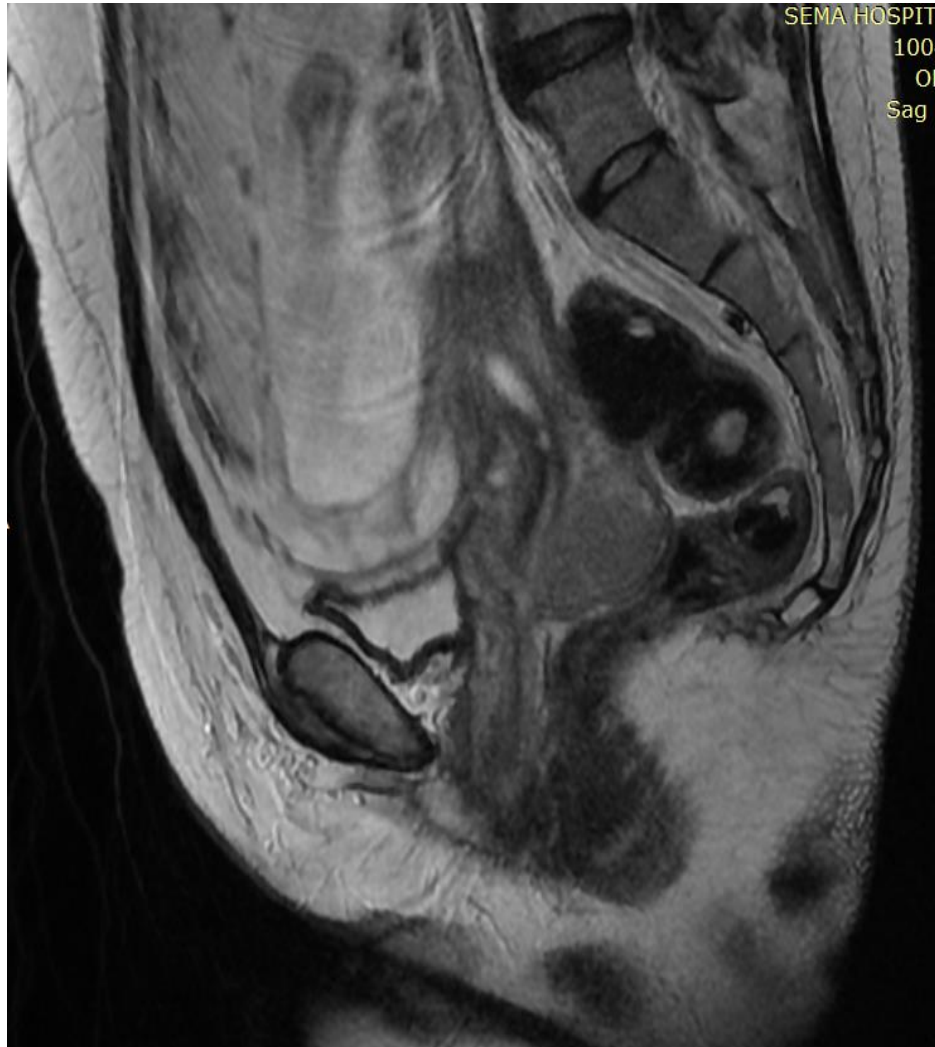
Transabdominal and transvaginal ultrasound from August 10, 2021:20⁺³ weeks of gestational age. Tumor of cervix (cervical myoma). Color Doppler ultrasonography revealed a single live fetus.

Abdomen MRI: no evidence for abdomen metastasis



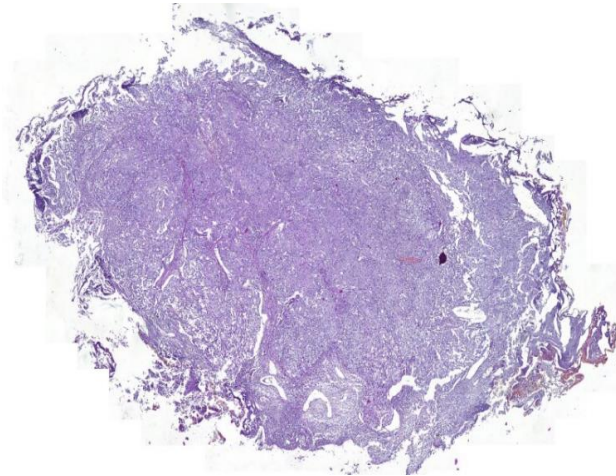
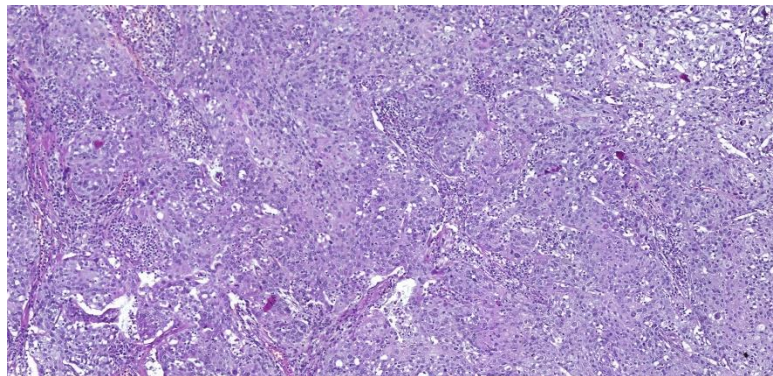
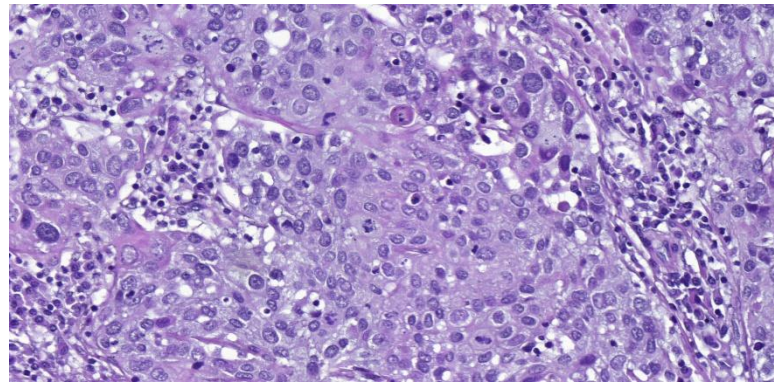
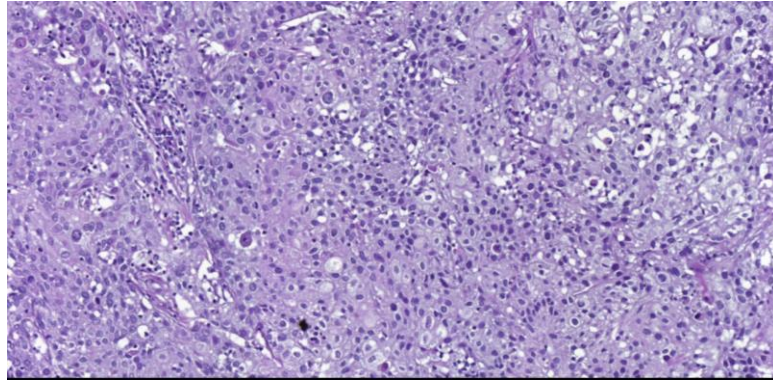
Pelvic MRI:

Tumor of cervix with size 4 cm. Pelvic lymph nodes are not enlarged



September 1, 2021 Biopsy of cervical tumor

Morphological findings
_squamous cell
carcinoma

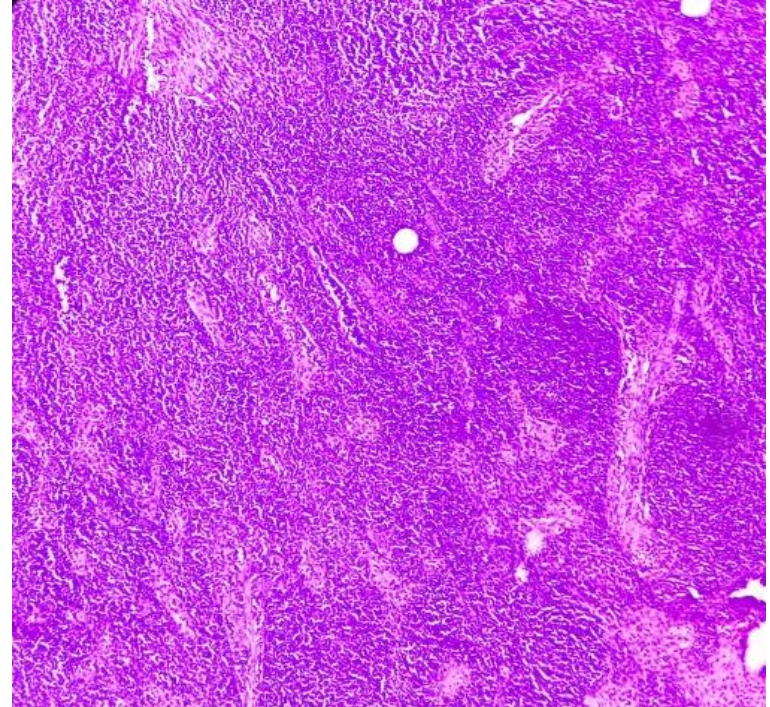
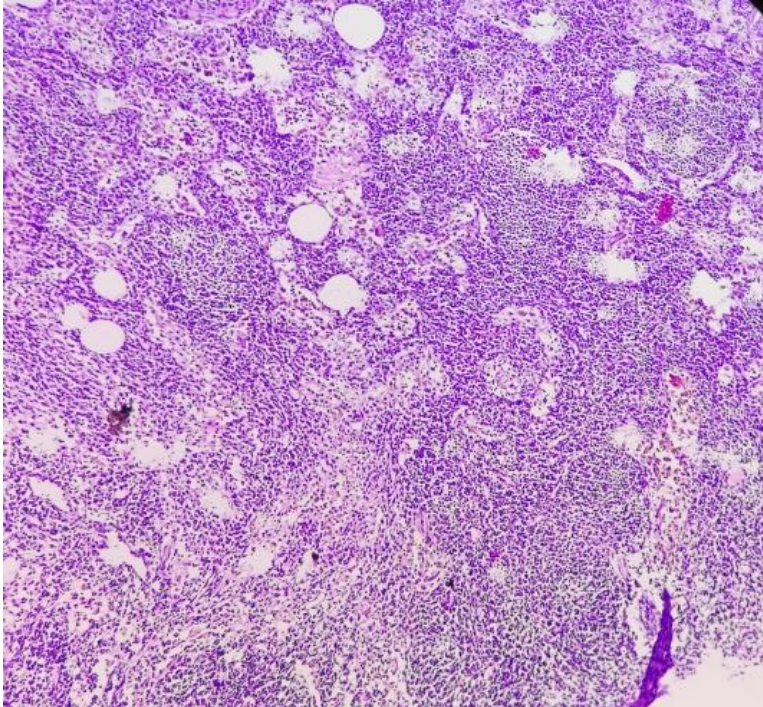


Patient refused from offered chemotherapy

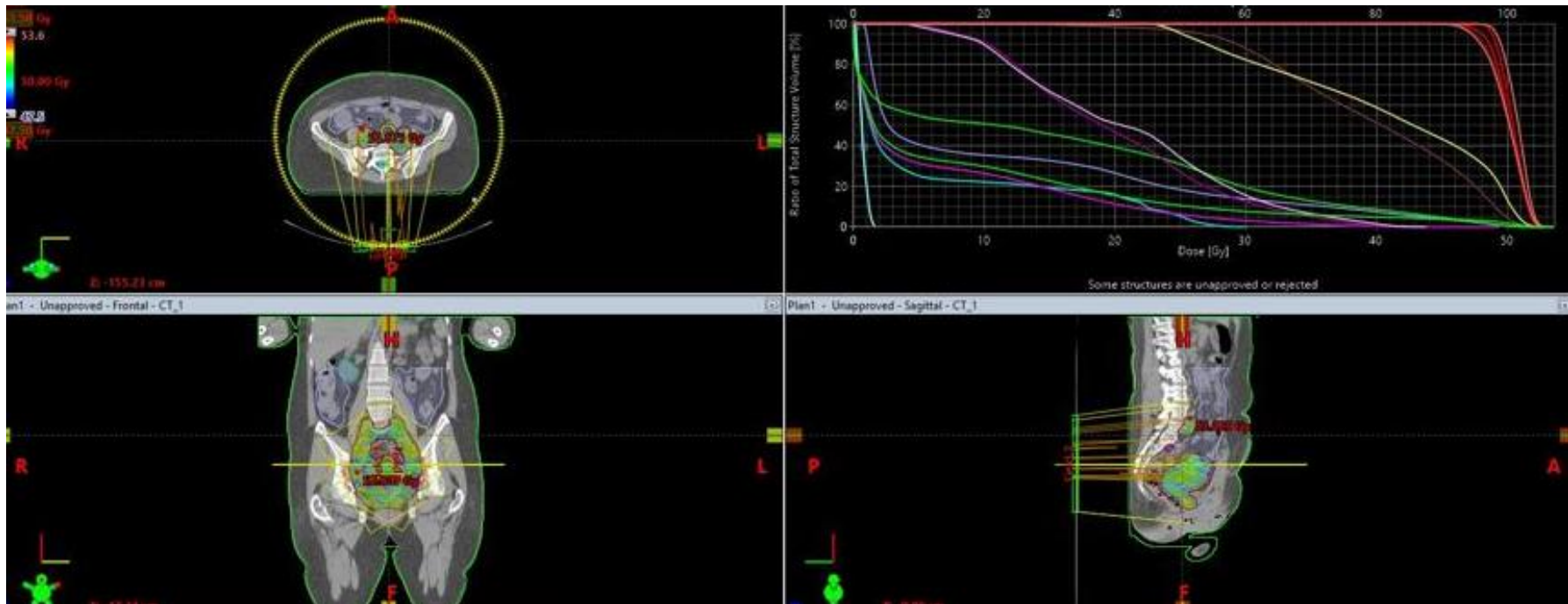
Stage IB1 squamous cell carcinoma of the cervix;
G4P3 27⁺³ weeks of a single live fetus.

- Case was discussed at September 2021 session IGCS ECHO project.
- Recommended: Cesarean section. Pelvic lymphadenectomy
- Chemoradiation therapy
- October 17, 2021 Cesarean section. Pelvic lymphadenectomy. Bilateral salpingectomy. Ovarian transposition at 34 week of gestation

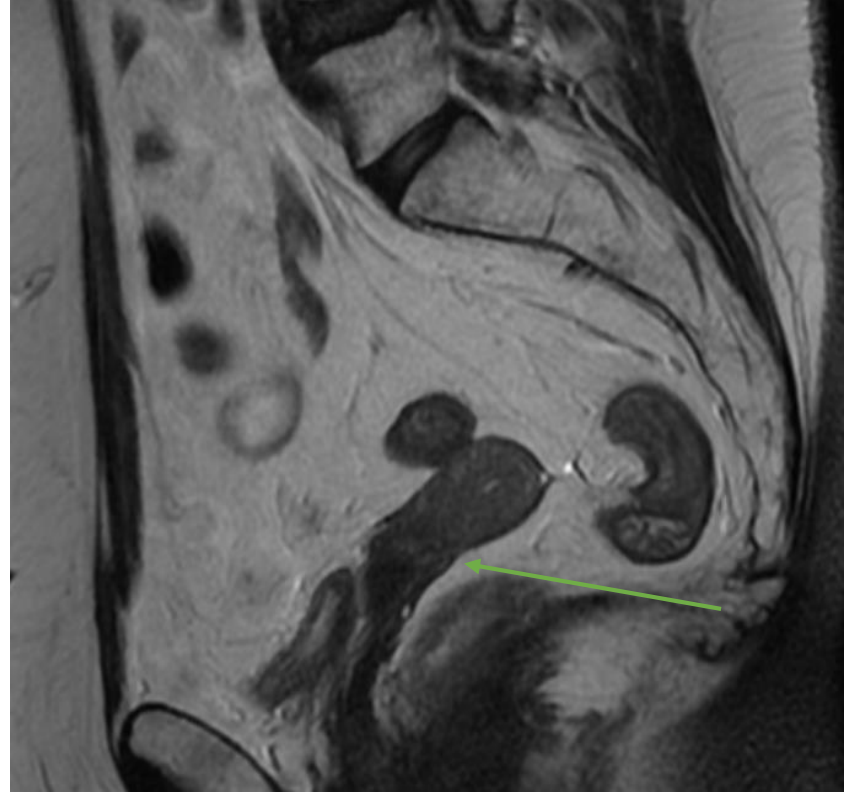
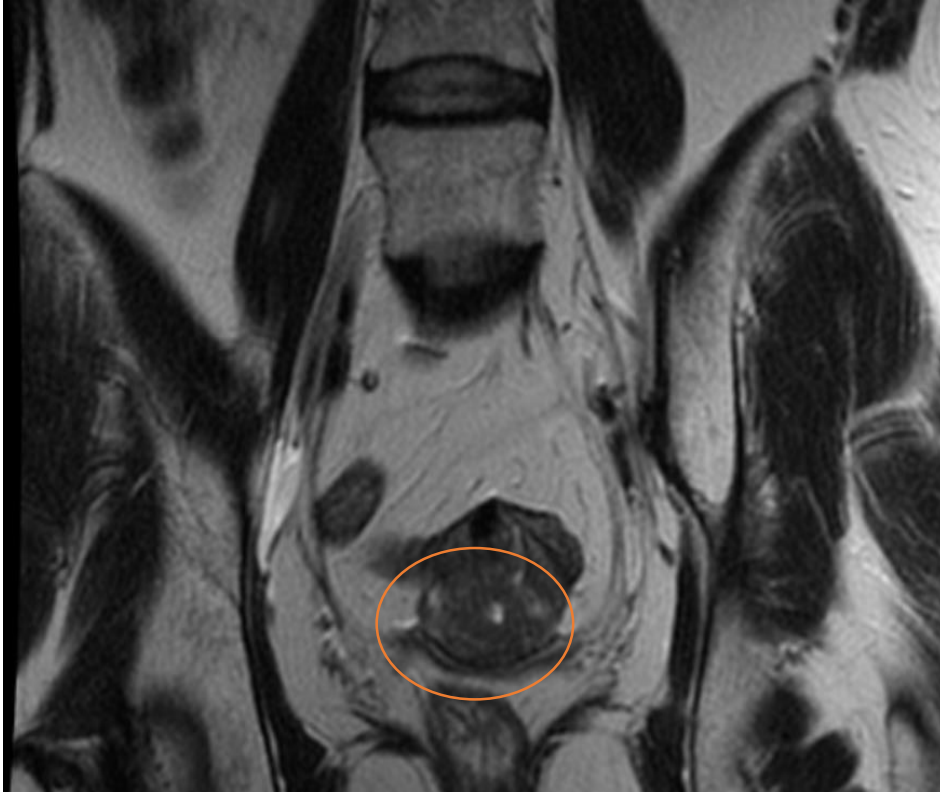
Histological findings: there is no tumor metastasis in the pelvic lymph nodes



- November 18 -December 30, 2021 Patient I. received radiation therapy.
- EBRT Total Dose 50 Grey
- Brachytherapy Total Dose 28 Grey



Pelvic MRI from September 15, 2022
no evidence of tumor recurrence



ECHO Project

Since 2017:

- ❖ over 50 sessions
- ❖ over 80 cases were discussed
- ❖ Over 45 didactics

Countries:

- IGCS experts (USA, Europe, Australia, Asia)
- ❖ Central Asia (Kazakhstan, Tajikistan, Kyrgyzstan, Mongolia)
- ❖ Caucasus (Georgia, Azerbaijan, Armenia)

